

The surgical rationale and the operative technique of sulcus-deepening trochleoplasty for the treatment of recurrent patellar dislocation with severe trochlear dysplasia

Trohleoplastika: Kirurške indikacije i operacijska tehnika u liječenju rekurentne patelarne dislokacije pri uznapredovaloj patelofemoralnoj displaziji

David H. Dejour^{1*}, Panagiotis G. Ntangiopoulos²

¹Lyon-Ortho-Clinic, Lyon, France

²Mediterraneo Hospital, Hip & Knee Unit, Athens, Greece

Received: 16.11.2014

Accepted: 20.12.2014

Abstract. Trochleoplasty is a surgical procedure which was initially reserved for the refractory cases where previous surgery has failed, but has become more popular in the past years because of a better knowledge of the knee anatomy and biomechanics and a greater availability of surgical instruments. The technical difficulty of the sulcus-deepening trochleoplasty lies in the fact that surgeons aim to reshape a usually extremely dysplastic articular surface of the trochlea without damaging it. If patients are carefully selected and the surgical rationale is carefully followed, recent bibliography presents very encouraging results of the application of trochleoplasty with other procedures in patients with severe trochlear dysplasia and recurrent patellar dislocation, in whom benign neglect of dysplasia would lead to unfavourable results. The surgical steps and technical pearls of the procedure are described in this review.

Key words: dislocation; dysplasia; patella; treatment; trochlea

Sažetak. Trohleoplastika je kirurški zahvat koji se koristi u liječenju rekurentnih dislokacija patele kod displazija patelofemoralnog zgloba. U početku se trohleoplastika primjenjivala samo kod pacijenata kod kojih ostale metode nisu polučile uspjeh. Kako saznanja o anatomiji i biomehanici napreduju, kao i tehnološka dostignuća u konstruiranju kirurških instrumenata, tako raste i popularnost takve vrste kirurškog zahvata raste. Radi se o zahtjevnom kirurškom zahvatu kod kojeg je potrebno preoblikovati displastično promijenjenu trohlee femura, a da se pritom značajno ne ošteti zglobna hrskavica. Noviji rezultati u pacijenata s visokim stupnjem displazije trohlee femura i rekurentnim dislokacijama patele, govore u prilog trohleoplastike u usporedbi s ostalim kirurškim postupcima. Ovaj rad u detalje opisuje kiruršku tehniku trohleoplastike.

Ključne riječi: dislokacija; displazija; liječenje; patella; trohlea

***Corresponding author:**

David H. Dejour, MD
Lyon-Ortho-Clinic,
29 Avenue des sources BAT B
Lyon 69009, France
e-mail:
dejour.secretariat@lyon-ortho-clinic.com

Note: Certain parts of this article were primarily published in the book *The Patellofemoral Joint: State of the Art in Evaluation and Management* (Gobbi A, Espregueira-Mendes J, Nakamura N. Springer Heidelberg New York Dordrecht London. 2014.), chapter 23 ("Sulcus-deepening trochleoplasty for the treatment of recurrent patellar dislocation with high-grade trochlear dysplasia").

<http://hrcak.srce.hr/medicina>

INTRODUCTION

Trochleoplasty is a surgical procedure which will help the surgeon to reshape a severely dysplastic trochlea without damaging its cartilage. Similar surgeries that reshape the articular surface of a bone are rare in orthopaedics and are predominantly reserved as salvage options¹. The goal of trochleoplasty is quite ambitious because this surgery changes what natural evolution has done during bone growth (Figure 1) without violating the cartilage of the usually young and adolescent patients that present with recurrent patellar dislocation. The modification of the congruency between the two articulating bones, and the alteration of joint kinematics are fundamental for long-term joint preservation; the technical difficulty of trochleoplasty lies in the fact that these two parameters must both be changed enough to correct patellar dislocation, but not altered in a way that could potentially lead to early arthritis².

The reason for this drastic surgical choice is to achieve stability and congruency in patients with recurrent patellar dislocation and severe trochlear dysplasia. Continuous stability of the patellofemoral (PF) joint throughout the whole knee range of motion is of absolute importance for the normal function of the extensor mechanism, the human erect stance and bipedalism. A better knowledge of joint anatomy and biomechanics has made trochleoplasty more popular in recent years, and the abundance of surgical instrumentation and imaging technology has also allowed surgeons to attempt more extreme procedures³. Four trochleoplasty procedures have been proposed; Albee's pioneer procedure involved the elevation of the lateral facet in order to restore normal anatomy⁴. The second procedure is the 'sulcus-deepening trochleoplasty', which was first proposed by Masse⁵ and later modified by Henri⁶. The third procedure was introduced by Bereiter and Gautier in 1994⁷, later to be followed by von Knoch⁸, known as the 'Bereiter procedure'. In this procedure, an osteochondral flake with only 2 mm of subchondral bone is elevated from the trochlea without osteotomy of the condyle, and the distal femoral subchondral bone is deepened with osteotomes and a high-speed burr. The same procedure has been performed arthroscopically by

Blønd and Schöttle⁹. The fourth procedure is the 'recession wedge trochleoplasty', which was introduced by Goutallier¹⁰ in 2002 and its results were later published by Beaufils². In this technique, the trochlea's shape is not changed, but removing a proximally-based wedge results in a more posteriorly-placed trochlea.

In 2010, D. Dejour introduced the sulcus-deepening trochleoplasty with the combination of soft-tissue procedures for the treatment of recurrent patellar dislocation in patients with underlying

The ideal indication for trochleoplasty is a true and documented patellar dislocation with underlying high-grade (type B and D) trochlear dysplasia, especially after previous failed surgery. Painless re-location of the patella by the patient or during clinical examination most definitely shows severe trochlear pathology.

high-grade trochlear dysplasia (Type B and D), as a modification of the 'Lyon's School' procedure¹¹. This new surgical technique was also the result of the more meticulous analysis of the 4 types of dysplasia and the introduction of a new and the so-far most consistent classification of trochlear dysplasia¹². The goal of this surgical procedure is to restore the normal anatomy and to re-shape the trochlea by undermining the cancellous bone and deepening the groove. The amount of bone removal is determined by the amount required to have a new trochlear groove flushed with the anterior femoral cortex and to make the bony prominence disappear. Furthermore, the trochlea is osteotomized with a scalpel carefully over the position of the 'desired' new trochlear groove. In this technique, the new trochlear groove is positioned according to the preoperative TT-TG value in a more lateral position, in order to reduce an excessive TT-TG value within normal limits.

THE RATIONALE OF THE SULCUS-DEEPENING TROCHLEOPLASTY

The rationale of the sulcus-deepening trochleoplasty is:

- to undermine the subchondral bone of the trochlea and to create a thick osteocartilaginous flap (in order not to damage the viability of the articular side),

- to remove enough cancellous bone posterior to the trochlea so that the prominence (the “spur”) disappears,
- to deepen the trochlear enough to its normal values, so that the sulcus angle is decreased. In cases of a flat or convex trochlea, trochleoplasty will create a more anatomic and concave geometry by deepening the proximal sulcus, so that it engages the patella in early degrees of knee flexion¹¹. In cases of a convex trochlea, trochleoplasty removes the sulcus prominence that the patella needs to override during flexion, and that leads to patella dislocation over the lateral facet.
- if required, by the presence of an increased pre-operative Tibial Tuberosity-Trochlear Groove (TT-TG) distance of over 20 mm, to perform a ‘proximal’ re-alignment procedure by osteotomizing the trochlea in a new and more lateral position, thus decreasing the TT-TG distance without the need to perform a TT medicalization osteotomy¹¹.

SURGICAL INDICATIONS

The ideal indication for trochleoplasty is a *true and documented patellar dislocation* with underlying high-grade (type B and D) trochlear dysplasia, especially after previous failed surgery. Painless re-location of the patella by the patient or during clinical examination, most definitely shows severe trochlear pathology.

PF arthritis, skeletally immature patients, and *isolated PF pain* with no true episodes of patellar dislocation are not suitable candidates for sulcus-deepening trochleoplasty.

Sulcus-deepening trochleoplasty is always combined with other soft-tissue procedures (such as medial patellofemoral ligament reconstruction) and possibly with bony procedures (TT osteotomies), when this is needed according to the “menu à la carte” introduced by the Lyon Group of H. Dejour¹³.

PRE-OPERATIVE EVALUATION

Pre-operative patient evaluation includes:

Clinical examination:

- positive apprehension test, excessive lateral patellar glide test (> 4 quadrants) and abnormal patellar tracking and positive J-sign,

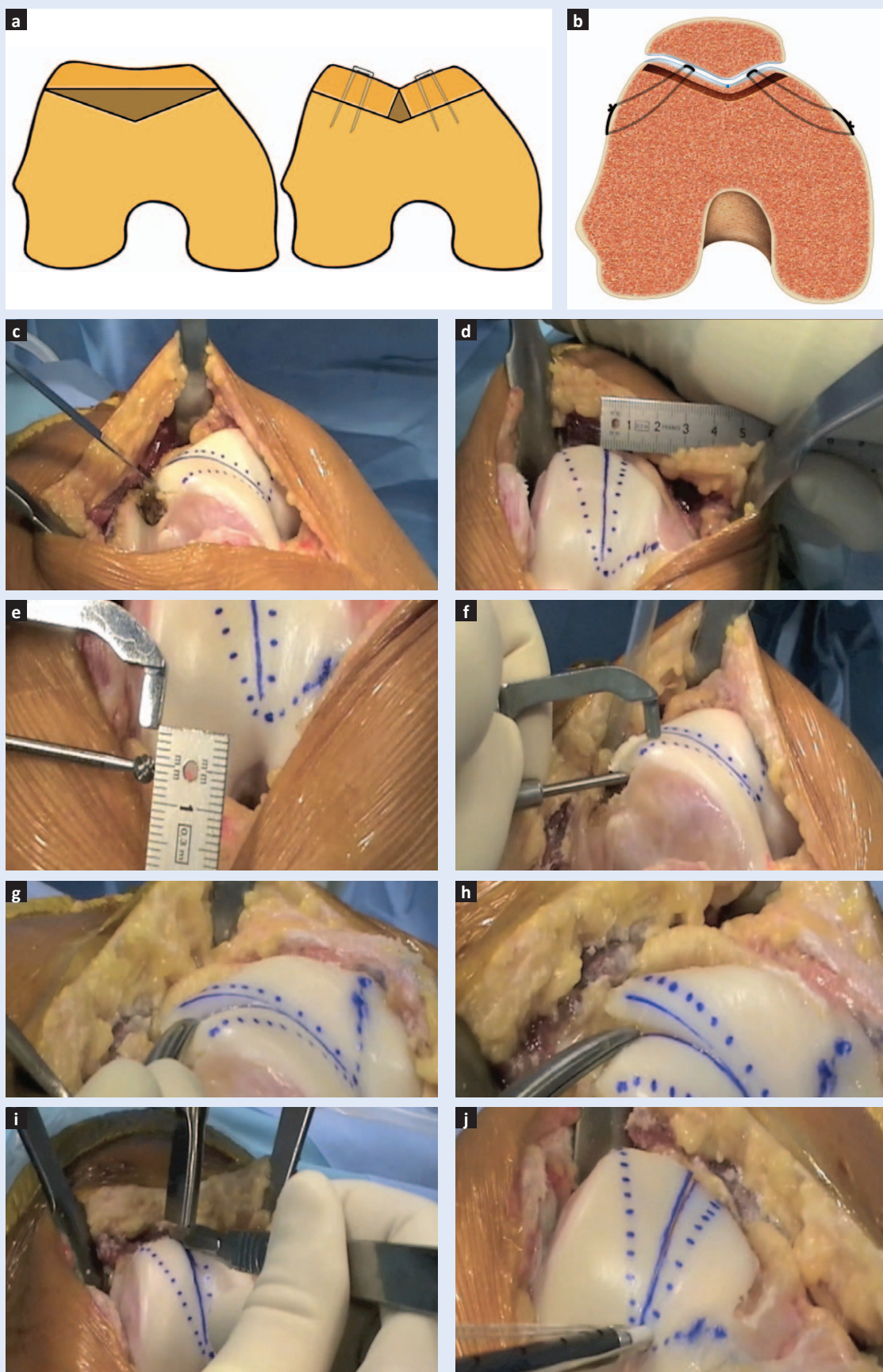
- subjective evaluation: presence of patellofemoral pain and/or feeling of patellar instability. History of voluntary patellar dislocation, permanent patellar dislocation (of congenital origin), habitual patellar dislocation (every time the knee flexes), and especially painless relocation of the dislocated patella by the patient or by the physician during examination, show severe trochlear pathology.
- the presence of abnormal, contracted or shortened extensor mechanism with patella alta or patella infera are also crucial to note. This will help the surgeon to estimate the amount or the absence of patellofemoral engagement.

Radiographic examination:

- standard X-rays are of huge value in patellofemoral disorders. Surgeons must evaluate the type of trochlear dysplasia in true lateral X-rays in standing position, 20° of knee flexion and absolute superimposition of the posterior femoral condyles. This is advised to be done usually under direct fluoroscopy and the supervision of the treating physician. Even minor rotation of the knee by a few degrees can underestimate the presence of any of the dysplasia signs (“crossing sign”, “supratrochlear spur”, etc.). In the same lateral views measurement of patellar height according to Caton-Deschamps index¹⁴ must be performed. Special attention is also given in lateral views to evaluate the tilt of the patella. Axial views help to measure the sulcus angle in patellar axial views in 30° of knee flexion.
- slice imaging with Computed Tomography (CT) or Magnetic Resonance Imaging (MRI) are useful to confirm the presence and the type of dysplasia (axial views) and to measure the Tibial tuberosity – trochlear groove (TT-TG) distance and lateral patellar tilt (without quadriceps contraction). Sagittal MRI views are useful to evaluate any trochlear prominence and to measure the sagittal PF engagement between the trochlea and the patella¹⁵.

THE NEED FOR ADDITIONAL SURGERIES

Patients with recurrent patellar dislocation and trochlear dysplasia are treated according to the



presence of concomitant predisposing anatomic abnormalities and trochleoplasty is combined with other procedures when needed^{12,13,16-19}:

- if the TT-TG distance is excessively increased (e.g. over 25 mm) a tibial tuberosity medialization osteotomy is performed in order to obtain post-operatively a TT-TG between 10 and 15 mm^{12,13}. In cases where the TT-TG distance is between 20-25 mm, a "proximal re-alignment procedure" can be done by lateralizing the new trochlear groove during trochleoplasty in a more lateral procedure, thus reducing the slightly increased TT-TG.
- if patella alta is recorded (Caton-Deschamps index > 1.3), a distalization osteotomy is done to obtain a normal patellar index of 1.0^{12,13}. In cases where a slightly elevated Caton-Deschamps index is recorded (e.g. 1.2-1.3), trochleoplasty alone was performed, even though this resulted in a slight patella alta.
- if the lateral patellar tilt is over 20° the correction is achieved with a reconstruction of the medial patellofemoral ligament (MPFL) using a double-looped gracilis graft^{12,13,20,21} and lateral retinaculum release/lengthening.

SURGICAL TECHNIQUE

Trochleoplasty is performed according to Dejour's 'sulcus-deepening trochleoplasty' in all patients¹¹. The principle is to remove subchondral cancellous bone under the trochlea with a high-speed burr (Figure 1a,b). The amount of bone removal is determined to have a new trochlear groove flushed with the anterior femoral cortex and to make the prominence disappear. The goal is to decrease the trochlear bump and deepen the sulcus angle.

Trochleoplasty can be performed under general or regional anaesthesia. The patient is positioned supine and the lower limb is prepared and draped in a standard fashion. A tourniquet is applied and the knee is flexed at 90°. A straight midline skin incision is carried out from the superior patellar margin to the tibiofemoral articulation. The arthrotomy is performed through an adapted midvastus approach: the medial retinaculum is sharply dissected 2 cm of the medial border of the patella and the vastus medialis oblique

(VMO) is bluntly dissected within its fibers starting proximally 3-4 cm into the muscle belly and ending at the superomedial pole of the patella. The patella is then briefly everted only to inspect and document chondral injuries and then it is retracted laterally.

The trochlea is now exposed and the peritrochlear synovium and periosteum are incised along their osteochondral junction and reflected from the field using a periosteal elevator. It is very important to visualize the level of the anterior femoral cortex in order to evaluate the exact height of the prominence and determine the amount of required deepening, by removing with an osteotome the prominent bone superiorly to the trochlear and up to the anterior femoral cortex (e.g. supratrochlear spur) (Figure 1c).

Once the trochlea is fully exposed, the native trochlear groove, medial and lateral facets are marked with 3 lines starting point from the intercondylar notch. The new trochlear groove is marked in a more lateral position according to the pre-operative TT-TG value (e.g. "proximal re-alignment" in order to get a post-operative value of 10-15 mm) (Figure 1d).

With the use of a burr with a 5 mm offset, undermining the cancellous bone posteriorly of the trochlear cartilage is performed (Figure 1e).

The burr must reach down to the intercondylar notch, but with care not to damage the cartilage (Figure 1f).

When sufficient cancellous bone has been removed, the trochlea must be elastic when applying light pressure with the fingers. When the trochlea is pressed down to the level where it is flush with the anterior femoral cortex (e.g. removal of the prominence) and moves backwards like a 'trampoline' when we remove the pressure, sufficient bone has been removed (Figure 1g).

The trochlea is then osteotomized with a scalpel carefully over the position of the desired new groove (Figure 1h,i).

At this point, if the trochlear facets are too rigid and it is difficult to suppress them, a further osteotomy over the medial and/or the lateral facet may be required. The trochlear facets are fixed with 2 absorbable anchor sutures from the intercondylar notch while applying pressure posteri-

only and evaluating that the prominence is removed and they are flush with the anterior femoral cortex (Figure 1j).

Lateral retinaculum release is performed after the trochleoplasty and it is mostly dependent on the ability of the examiner's to evert the patella inwards (e.g. no lateral release is required) or not (e.g. lateral structures are tightened and lateral release is required). The joint capsule is then closed. MPFL reconstruction is performed last, with the surgeon's preferred technique. No drain is used and the knee is put in an extension brace with no restriction in weight bearing. Prophylactic anticoagulants are advised for 2-3 weeks.

REHABILITATION PROTOCOL

The standard post-operative rehabilitation protocol for trochleoplasty patients includes: immediate full weight bearing with the use of crutches in an extension knee brace for 15 days is allowed. Continuous passive motion between 0° and 100° is advised within the first 2-3 days as the pain and the swelling subside. The first 6 weeks, the patients are encouraged to perform exercises for early range of pain-free motion, and isometric quadriceps and hamstring strengthening. From 6th to 12th post-operative week, the protocol also includes closed-chain and weight bearing proprioception exercises.

After 12th post-operative week, patients start running and gradually training in their sport of preference and are allowed to full sports activities after 6 months. During this period (3-6 months post-operatively) running can be initiated on a straight line alone. Closed kinetic chain muscular reinforcement between 0-60° with minor loads, but long series is also allowed. Stretching of the anterior and posterior muscular chains is continued as during the previous phases. The patient is encouraged to proceed with the rehabilitation on his or her own. After 6 months, sports on a recreational or competitive level can be resumed progressively.

DISCUSSION

Trochleoplasty procedures are more and more widely performed as a primary and especially as a revision option in selected patients with recurrent patellar dislocation and underlying trochlear

dysplasia. Trochlear dysplasia has been identified as the most recognized factor in patients with patellofemoral dislocation and present in 96 % of patients with patellar dislocation¹³. On the other hand, there are only a small number of surgeons who perform trochleoplasty for the treatment of patellar dislocation², in comparison to tibial tuberosity osteotomy for re-alignment procedures or patella alta, or more recently MPFL reconstruction. Therefore, there is a significant group of patients with patellofemoral instability in

The combination of the procedure with soft-tissue surgery, such as MPFL reconstruction, is necessary to achieve patellar stability. There is need for agreement on the choice of the right candidate for trochleoplasty, the surgical technique, the rehabilitation protocol, and the post-operative parameters that must be corrected. Sulcus-deepening trochleoplasty requires careful attention to detail.

whom the key aetiological factor of instability, the trochlear dysplasia, is under-estimated or not addressed.

However, in the last years, a number of publications have presented results from over three hundreds patients treated with different techniques of trochleoplasty^{2,6-10,22-36}. Despite the different surgical rationale behind each technique, all these authors present extremely successful results in terms of recurrence of dislocation. Residual pain or stiffness may complicate surgery but patellar re-dislocation is extremely rare among these results. Trochleoplasty is surely not a first option for any patient with patellar dislocation, but should be tried in patients with high-grade trochlear dysplasia, in whom the patella cannot override the severe trochlear bony prominence during early flexion.

The mid- and long-term results of the sulcus-deepening trochleoplasty are encouraging. Ntgiopoulos et al. have shown improved radiological parameters (significantly decreased sulcus angle TT-TG distance and lateral patellar tilt) in 27 patients with patellar dislocation and no previous PF surgery³¹. In the same study of the Lyon group, no recurrence was observed, and there was no

case of stiffness, even though the apprehension sign remained positive in 19.3 % of the cases³¹. Most important, there was no radiographic evidence of PF arthritis. The results of trochleoplasty are equally encouraging for the population that needs revision PF surgery due to unsuccessful previous operations. In 2012, Dejour et al. presented the results after trochleoplasty in 24 knees with previous surgery and recurrence of patellar dislocation²⁵. The authors recorded no patellar re-dislocation up to the last follow-up, while the knee pain decreased in 72 % and the apprehension sign was negative in 75 % of the cases ($p < 0.01$). The sulcus angle, TT-TG distance and lateral patellar tilt also decreased significantly. In this patient group of young age there was no case of patellofemoral arthritis at the time of the last follow-up²⁵. Other authors also present different results in terms of post-operative functional scores, the presence of post-operative apprehension sign, or crepitus, but they all present almost 0 % of redislocation rate after trochleoplasty^{2,25,26,31,34,37-39}. The possible damage of cartilage after trochleoplasty seems to be minimal but is also difficult to evaluate in these patients, in whom it is well-established that the recurrent patellar dislocation – if left untreated – will eventually lead to PF osteoarthritis⁴⁰.

The goal of sulcus-deepening trochleoplasty is to re-shape the abnormal trochlear shape, but the instability of the patella is also caused by the presence of co-existent anatomic factors that must be addressed (e.g. tuberosity osteotomy for patella alta or increased TT-TG distance), and its treatment almost always requires a combined soft-tissue procedure like MPFL reconstruction^{11,12,41}. This is because patellar stability during early flexion is accomplished by MPFL, which is tight in full knee extension and acts as a dynamic stabilizer during early flexion (15°-20°), brings the patella into the trochlear groove, which is necessary for the normal further tracking of the patella, and in greater degrees of flexion (> 30°) is loose and the normal concave trochlear geometry acts as a static stabilizer^{13,18,42,43}. MPFL rupture is the consequence of pathologic lateral patellar translation, while the actual causes are the underlying bony abnormalities like trochlear dysplasia

and patella alta^{13,41} and, most importantly, a normal trochlea with a deep groove and an elevated lateral facet is necessary for MPFL to provide stability^{41,44}. This is the reason why, although MPFL has a fundamental role in patellar stability, isolated MPFL reconstruction should not be considered a panacea for patellar dislocation, without excluding the presence of other factors contributing to instability⁴¹ that need associated correction^{2,8,10-12,18,28,30,34,35}.

In the case of a convex trochlea, there is a centrally located sulcus prominence that the patella needs to override during flexion and which leads to patella dislocation off the lateral facet^{45,46}. This prominence is present in type B and D trochlear dysplasia, where the central groove is elevated. In this scenario of underlying high-grade trochlear dysplasia, if patellar dislocation is approached with no regard to dysplasia and the elevated groove, and is addressed by medial soft-tissues augmentation alone, the patella will obtain firm medially stabilizing structures and a medial tilt, but the elevated and abnormal trochlear groove will still be present. This could lead to undesirable impingement between the patella and the trochlear prominence and the subsequent increased contact pressures and graft loosening, effects similar to overmedializing the patella after MPFL reconstruction^{16,47} or to the pattern of MPFL rupture recorded in patients with trochlear dysplasia⁴⁸.

If patellar dislocation is approached with no regard to dysplasia and the elevated groove, and is addressed by medial soft-tissues augmentation alone, the patella will be positioned medially in front of an untreated elevated groove that would lead to impingement between the patella and the trochlear (Figure 2).

In a different scenario, the isolated correction of patella alta and the under-estimation of a concomitant high-grade trochlear dysplasia would have similar inefficient results to treat patellar dislocation; a distalization osteotomy of the tuberosity would normalize patellar height, but would only lower the patella in front of an abnormally shaped trochlear groove, if trochlear dysplasia were not corrected. The absence of a deep trochlear groove would not provide to the patella

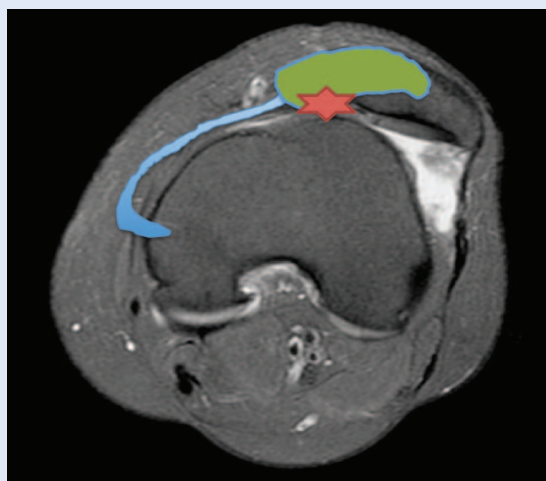


Figure 2. If patellar dislocation is approached with no regard to dysplasia and the elevated groove (blue), and is addressed by medial soft-tissues augmentation alone (green), the patella will be positioned medially in front of an untreated elevated groove that would lead to impingement between the patella and the trochlear (red).

the required lateral stability from further lateral dislocation.

In the clinical setting, other authors report success rates from 90 % to 100 % after trochleoplasty procedures^{8,10,28,34-36}. After trochleoplasty, recurrence of dislocation is highly uncommon and patient satisfaction is high¹⁸. The results of trochleoplasty as a revision option in selected patients who had previous failed surgery for patellofemoral instability have been recently recorded²⁵.

CONCLUSION

In conclusion, trochleoplasty is an important surgical option both as a primary and as a revision option in the case of previously operated patients with persistent patellar dislocation and undiagnosed or underestimated trochlear dysplasia. The combination of the procedure with soft-tissue surgery, such as MPFL reconstruction, is necessary to achieve patellar stability. There is need for agreement on the choice of the right candidate for trochleoplasty, the surgical technique, the rehabilitation protocol, and the post-operative parameters that must be corrected. Sulcus-deepening trochleoplasty requires careful attention to detail. It is a technically-demanding procedure that addresses a rare condition with satisfactory results and acceptable level of com-

plications, and is more suitable for severe cases of type B and D of dysplasia, where the presence of trochlear prominence is amenable to correction with this technique.

Conflicts of interest statement: The authors report no conflicts of interest.

REFERENCES

1. Bollier M, Fulkerson JP. The role of trochlear dysplasia in patellofemoral instability. *J Am Acad Orthop Surg* 2011;19:8-16.
2. Beauflis P, Thaunat M, Pujol N, Scheffler S, Rossi R, Carmont M. Trochleoplasty in major trochlear dysplasia: current concepts. *Sports Med Arthrosc Rehabil Ther Technol* 2012;4:7.
3. Ntgiopoulos PG, Dejour D. Current concepts on trochleoplasty procedures for the surgical treatment of trochlear dysplasia. *Knee Surg Sports Traumatol Arthrosc* 2014;22:2531-9.
4. Albee FH. Bone graft wedge in the treatment of habitual dislocation of the patella. *Med Record* 1915;88:257.
5. Masse Y. Trochleoplasty. Restoration of the intercondylar groove in subluxations and dislocations of the patella. *Rev Chir Orthop Reparatrice Appar Mot* 1978;64:3-17.
6. Dejour H, Walch G, Neyret P, Adeleine P. Dysplasia of the femoral trochlea. *Rev Chir Orthop Reparatrice Appar Mot* 1990;76:45-54.
7. Bereiter H, Gautier E. Die trochleoplastik als chirurgische Therapie der rezidivierenden Patellaluxation bei Trochleadysplasie des Femurs. *Arthroscopie* 1994;7:281-6.
8. von Knoch F, Bohm T, Burgi ML, von Knoch M, Bereiter H. Trochleoplasty for recurrent patellar dislocation in association with trochlear dysplasia. A 4- to 14-year follow-up study. *J Bone Joint Surg Br* 2006;88:1331-5.
9. Blønd L, Schöttle PB. The arthroscopic deepening trochleoplasty. *Knee Surg Sports Traumatol Arthrosc* 2010;18:480-5.
10. Goutallier D, Raou D, Van Driessche S. Retro-trochlear wedge reduction trochleoplasty for the treatment of painful patella syndrome with protruding trochleae. Technical note and early results. *Rev Chir Orthop Reparatrice Appar Mot* 2002;88:678-5.
11. Dejour D, Saggin P. The sulcus deepening trochleoplasty-the Lyon's procedure. *Int Orthop* 2010;34:311-6.
12. Dejour D, Le Coultre B. Osteotomies in patello-femoral instabilities. *Sports medicine and arthroscopy review* 2007;15:39-46.
13. Dejour H, Walch G, Nove-Josserand L, Guier C. Factors of patellar instability: an anatomic radiographic study. *Knee Surg Sports Traumatol Arthrosc* 1994;2:19-26.
14. Caton J, Deschamps G, Chambat P, Lerat JL, Dejour H. Patella infera. Apropos of 128 cases. *Rev Chir Orthop Reparatrice Appar Mot* 1982;68:317-25.
15. Dejour D, Ferrua P, Ntgiopoulos PG, Radier C, Hulet C, Remy F et al. The introduction of a new MRI index to evaluate sagittal patellofemoral engagement. *Orthop Traumatol Surg Res* 2013;99 (8 Suppl):S391-8.
16. Colvin AC, West RV. Patellar instability. *J Bone Joint Surg Am* 2008;90:2751-62.

17. Dejour D, Saggin P. Disorders of the Patellofemoral Joint. In: Scott NW (ed). *Insall & Scott Surgery of the Knee*, vol 1. Insall & Scott Surgery of the Knee, 5 edn. Philadelphia: Elsevier, 2012;592-623.
18. Mulford JS, Wakeley CJ, Eldridge JD. Assessment and management of chronic patellofemoral instability. *J Bone Joint Surg Br* 2007;89:709-16.
19. Schoettle PB, Zanetti M, Seifert B, Pfirrmann CW, Fucentese SF, Romero J. The tibial tuberosity-trochlear groove distance; a comparative study between CT and MRI scanning. *Knee* 2006;13:26-31.
20. Arendt EA. MPFL reconstruction for PF instability. The soft (tissue) approach. *Orthop Traumatol Surg Res* 2009;95 (8 Suppl 1):S97-100.
21. Saggin PR, Saggin JI, Dejour D. Imaging in patellofemoral instability: an abnormality-based approach. *Sports Med Arthrosc* 2012;20:145-51.
22. Biedert RM. Trochlear lengthening osteotomy with or without elevation of the lateral trochlear facet. In: Arendt E, Dejour D, Zaffagnini S (eds). *Patellofemoral pain, instability and arthritis: clinical presentation and treatment*, vol 1. Springer, 2010;209-17.
23. Biedert RM, Netzer P, Gal I, Sigg A, Tscholl PM. The lateral condyle index: a new index for assessing the length of the lateral articular trochlea as predisposing factor for patellar instability. *Int Orthop* 2011;35:1327-31.
24. Blond L, Haugegaard M. Combined arthroscopic deepening trochleoplasty and reconstruction of the medial patellofemoral ligament for patients with recurrent patella dislocation and trochlear dysplasia. *Knee Surg Sports Traumatol Arthrosc* 2014;22:2484-90.
25. Dejour D, Byn P, Ntgiopoulos PG. The Lyon's sulcus-deepening trochleoplasty in previous unsuccessful patellofemoral surgery. *Int Orthop* 2013;37:433-9.
26. Dejour D, Ntgiopoulos PG, Saffarini M. Evidence of trochlear dysplasia in femoral component designs. *Knee Surg Sports Traumatol Arthrosc* 2011;22:2599-607.
27. Dejour DH. The patellofemoral joint and its historical roots: the Lyon School of Knee Surgery. *Knee Surg Sports Traumatol Arthrosc* 2013;21:1482-94.
28. Donell ST, Joseph G, Hing CB, Marshall TJ. Modified Dejour trochleoplasty for severe dysplasia: operative technique and early clinical results. *Knee* 2006;13:266-73.
29. Fucentese SF, Schöttle PB, Pfirrmann CW, Romero J. CT changes after trochleoplasty for symptomatic trochlear dysplasia. *Knee Surg Sports Traumatol Arthrosc* 2007;15:168-74.
30. Fucentese SF, Zingg PO, Schmitt J, Pfirrmann CW, Meyer DC, Koch PP. Classification of trochlear dysplasia as predictor of clinical outcome after trochleoplasty. *Knee Surg Sports Traumatol Arthrosc* 2011;19:1655-61.
31. Ntgiopoulos PG, Byn P, Dejour D. Midterm results of comprehensive surgical reconstruction including sulcus-deepening trochleoplasty in recurrent patellar dislocations with high-grade trochlear dysplasia. *Am J Sports Med* 2013;41:998-1004.
32. Schöttle PB, Fucentese SF, Pfirrmann C, Bereiter H, Romero J. Trochleoplasty for patellar instability due to trochlear dysplasia: A minimum 2-year clinical and radiological follow-up of 19 knees. *Acta orthopaedica* 2005;76:693-8.
33. Schöttle PB, Schell H, Duda G, Weiler A. Cartilage viability after trochleoplasty. *Knee Surg Sports Traumatol Arthrosc* 2007;15:161-7.
34. Thauinat M, Bessiere C, Pujol N, Boisrenoult P, Beaufile P. Recession wedge trochleoplasty as an additional procedure in the surgical treatment of patellar instability with major trochlear dysplasia: early results. *Orthop Traumatol Surg Res* 2011;97:833-45.
35. Utting MR, Mulford JS, Eldridge JD. A prospective evaluation of trochleoplasty for the treatment of patellofemoral dislocation and instability. *J Bone Joint Surg Br* 2008;90:180-5.
36. Verdonk R, Jansegers E, Stuyts B. Trochleoplasty in dysplastic knee trochlea. *Knee Surg Sports Traumatol Arthrosc* 2005;13:529-33.
37. Nelitz M, Dreyhaupt J, Lippacher S. Combined trochleoplasty and medial patellofemoral ligament reconstruction for recurrent patellar dislocations in severe trochlear dysplasia: a minimum 2-year follow-up study. *Am J Sports Med* 2013;41:1005-12.
38. Banke IJ, Kohn LM, Meidinger G, Otto A, Hensler D, Beitzel K et al. Combined trochleoplasty and MPFL reconstruction for treatment of chronic patellofemoral instability: a prospective minimum 2-year follow-up study. *Knee Surg Sports Traumatol Arthrosc* 2014;22:2591-8.
39. Duncan ST, Noehren BS, Lattermann C. The role of trochleoplasty in patellofemoral instability. *Sports medicine and arthroscopy review* 2012;20:171-80.
40. Maenpaa H, Lehto MU. Patellofemoral osteoarthritis after patellar dislocation. *Clin Orthop Relat Res* 1997;339:156-62.
41. Arendt EA, Fithian DC, Cohen E. Current concepts of lateral patella dislocation. *Clin Sports Med* 2002;21:499-519.
42. Arendt E. Anatomy and malalignment of the patellofemoral joint: its relation to patellofemoral arthrosis. *Clin Orthop Relat Res* 2005;436:71-5.
43. Senavongse W, Amis AA. The effects of articular, retinacular, or muscular deficiencies on patellofemoral joint stability: a biomechanical study in vitro. *J Bone Joint Surg Br* 2005;87:577-82.
44. Bicos J, Fulkerson JP, Amis A. Current concepts review: the medial patellofemoral ligament. *Am J Sports Med* 2007;35:484-92.
45. Amis AA, Oguz C, Bull AM, Senavongse W, Dejour D. The effect of trochleoplasty on patellar stability and kinematics: a biomechanical study in vitro. *J Bone Joint Surg Br* 2008;90:864-9.
46. Biedert RM, Bachmann M. Anterior-posterior trochlear measurements of normal and dysplastic trochlea by axial magnetic resonance imaging. *Knee Surg Sports Traumatol Arthrosc* 2009;17:1225-30.
47. Panagopoulos A, van Niekerk L, Triantafillopoulos IK. MPFL reconstruction for recurrent patella dislocation: a new surgical technique and review of the literature. *Int J Sports Med* 2008;29:359-65.
48. Weber-Spickschen TS, Spang J, Kohn L, Imhoff AB, Schöttle PB. The relationship between trochlear dysplasia and medial patellofemoral ligament rupture location after patellar dislocation: an MRI evaluation. *Knee* 2011;18:185-8.