

## Case Report

## Postpartum Pulmonary Arterial Hypertension: Two Cases Covering a Wide Spectrum of Presentations

EFTYCHIA DEMEROUTI<sup>1</sup>, ATHANASSIOS MANGINAS<sup>1</sup>, SPYRIDON RAMMOS<sup>2</sup>,  
GEORGE ATHANASSOPOULOS<sup>1</sup>, GEORGE KARATASAKIS<sup>1</sup>, GREGORY PAVLIDES<sup>1</sup>

<sup>1</sup>First Cardiology Department, <sup>2</sup>Department of Pediatric Cardiology, Onassis Cardiac Surgery Centre, Athens, Greece

## Key words:

**Pregnancy, right ventricular failure, lung transplantation, balloon atrial septostomy.**

We present two clinical cases of pulmonary arterial hypertension (PAH) diagnosed after pregnancy. Both patients experienced exertional breathlessness during the third month after their uncomplicated delivery, and idiopathic PAH was diagnosed after an integrated assessment. Our first patient, a 30-year-old woman, was vasoreactive, treated with optimally tolerated doses of calcium channel blockers with adequate response, and she has remained in a stable and satisfactory condition for the last seven years. The second patient, a 34-year-old woman, was non-vasoreactive and had an inadequate response to combination therapy, including prostanoids. Balloon atrial septostomy was performed as a bridge to lung transplantation, however she expired five months after her delivery.

Manuscript received:  
November 13, 2010;  
Accepted:  
May 13, 2011.

Address:  
Eftychia A. Demerouti

1st Cardiology Dept.  
Onassis Cardiac Surgery  
Centre  
356 Syngrou Avenue  
176 74 Kallithea  
Athens, Greece  
e-mail: [efidemer@otenet.gr](mailto:efidemer@otenet.gr)

**G**estation represents a major burden upon the cardiovascular system, but the necessary adjustments are usually well tolerated in healthy women. Hormonal activation and circulating vasoactive substances lead to decreased systemic vascular resistance, one of the earliest haemodynamic changes in pregnant women. Both blood volume and cardiac output (CO) rise by 30-50%, coagulation factors also rise, and fibrinolytic activities decrease.<sup>1</sup> The CO also increases during labour and delivery. The heart rate, the systemic vascular resistance, cardiac output, and cardiac dimensions start to improve within hours postpartum, but these alterations do not return to normal until months after the delivery.<sup>1</sup>

Several well-described heart conditions may develop in pregnancy or in parturition, including hypertension and pre-eclampsia, peripartum cardiomyopathy, pulmonary embolism, myocardial infarc-

tion (usually due to coronary dissection), as well as aortic dissection and tachyarrhythmias.<sup>2-5</sup> Pulmonary arterial hypertension (PAH), although a severe progressive disease, has not been yet well described in the postpartum period.

The exacerbation of underlying pulmonary hypertension in pregnancy is known to be associated with prohibitive maternal mortality, caused by the physiologic changes occurring during pregnancy and the puerperium,<sup>1</sup> thus in PAH patients pregnancy is contraindicated.

### Case presentation

Our patients were referred to our hospital complaining of progressive exertional breathlessness, firstly occurring during the third month after their full-term pregnancy. For both patients, the pregnancy was their second one, and their children were healthy. The evaluation process excluded

thromboembolic pulmonary hypertension (normal ventilation-perfusion lung scan), pulmonary veno-occlusive disease or pulmonary capillary haemangiomas (negative high-resolution CT scanning and clinical examination), and left-heart disease (systolic or diastolic dysfunction and valvular disease). Underlying lung disease was also excluded after a prompt pulmonary assessment. Normal abdominal ultrasound, blood serology and immunology tests excluded associated conditions, risk factors for PAH or haematological, systemic and metabolic disorders. The diagnosis of idiopathic or heritable PAH was established for both patients after right heart catheterisation (RHC).

### Case 1

Our first patient was initially in functional status class II according to the WHO (World Health Organisation) classification. Her RHC revealed the following parameters: mean pulmonary arterial pressure (PAP mean) at 30 mmHg, right atrial pressure (RAP) at 8 mmHg, pulmonary capillary wedge pressure (PCWP) 7 mmHg, with an estimated cardiac index (CI, Fick method) at 4.07 L/min/m<sup>2</sup>, and pulmonary vascular resistance (PVR) at 5 Wood units (WU). A vasoreactivity test was performed with inhaled nitric oxide at 10 ppm for 5 minutes, causing a reduction of PAP mean to 19 mmHg and PVR to 3 WU, with unchanged arterial blood pressure (BP) and cardiac index. The six-minute walk distance (6MWD) was 350 m and the N-terminal brain natriuretic peptide (NT-proBNP) level was 190 pg/ml (upper normal level 125 pg/ml). The echocardiogram revealed a mildly dilated right ventricle with a systolic pulmonary arterial pressure (PASP) of 60 mmHg and mild tricuspid regurgitation with normal right ventricular (RV) function. Her left ventricular (LV) function was also normal.

The patient was treated with nifedipine (120 mg per day) and prompt anticoagulation therapy, with an adequate clinical response from the second month of treatment. Three years later, the patient voluntarily stopped nifedipine, causing a rapid recurrence of symptomatic pulmonary hypertension within 72 hours. A new RHC revealed an increase in PAP mean, and the deterioration was rapidly controlled by reintroduction of nifedipine.

Our patient remains asymptomatic in a stable condition (clinical status WHO class I), on calcium channel blockers, fulfilling the majority of findings that predict a favourable prognosis. Her last 6MWD was 538 m and the echocardiogram revealed a PASP

of 52 mmHg with normal right ventricular function. NT-proBNP levels were within normal limits.

A repeat RHC was recommended, but the patient refused because of her good quality of life, only accepting a regular follow up every six months.

### Case 2

The second patient had no history of cardiopulmonary disease and her first pregnancy, five years before, was uncomplicated. Progressive breathlessness and occasional chest pain at rest began during the third month after her second delivery. First medical contact was sought during the fourth month postpartum, after four syncopal episodes. She was hospitalised and supported with dobutamine because of signs of RV failure. After being treated with inhaled prostanooids (iloprost), she was transferred to our cardiology department for intravenous (iv) prostanooids. She underwent RHC (Table 1), a Hickman catheter was implanted and iv treprostinil was initiated. She was discharged a month later, being in a stable condition after a long period without syncope or haemodynamic instability, on treprostinil at 10 ng/kg/min. The pre-discharge 6MWD was 207 m, and the NT-proBNP level had decreased to 2500 pg/ml (initially measured at 3800 pg/ml). Her follow-up visit had been planned for a month later, and her treatment included iv treprostinil, furosemide 40 mg and warfarin.

Unfortunately, 20 days after her discharge, while on iv treprostinil at a dose of 18 ng/kg/min, she was admitted to our intensive care unit with clinical evidence of RV failure, and pre-syncopal episodes. An echocardiogram revealed a D-shaped, small left ventricle with end-diastolic diameter 23 mm. The PASP was estimated at 95 mmHg, and the RV was dilated.

**Table 1.** Case 2. Haemodynamic parameters from right heart catheterisation at the first and second hospitalisations, and after balloon atrial septostomy (BAS).

	First	Second	After BAS
RA (mmHg)	5	21	18
RV (mmHg)	75/5	92/20	84/18
PA (mmHg)	75/25/42	92/41/60	69/32/48
CI (L/min/m <sup>2</sup> )	2.5	1.38	1.97
PVR (WU)	15	20.4	12.1
PCWP (mmHg)	8	10	12

RA – right atrial pressure; RV – right ventricular pressure; PA – pulmonary arterial pressure; CI – cardiac index; PVR – pulmonary vascular resistance; PCWP – pulmonary capillary wedge pressure.

ed with deteriorated function. The tricuspid annular plane systolic excursion was 12 mm and the RV S-wave velocity was measured at 7 cm/s by tissue Doppler imaging. A small pericardial effusion was also detected. Table 2 summarises the echocardiographic parameters on her first admission, at discharge, and during the second admission.

Among the laboratory tests, NT-proBNP was severely elevated at 8500 from 2500 pg/ml, and the biochemical values revealed abnormal liver and renal function.

A second RHC was performed with a PAP mean 60 from 42 mmHg, and a severely lower CI at 1.38 L/min/m<sup>2</sup> (Table 1). Addition of sildenafil was attempted and our patient was immediately referred for transplantation assessment. She was promptly accepted for lung transplantation abroad, and her transfer had been planned for that same week.

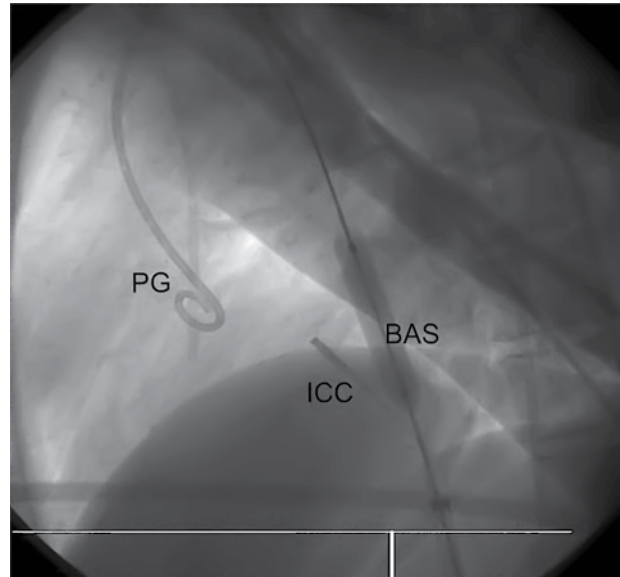
While the patient was waiting for air transfer, a balloon atrial septostomy (BAS) was performed with the collaboration of the paediatric department in our centre, because of repeated pre-syncopal episodes (4-5 per day). In a standard cardiac catheter laboratory under local anaesthetic, a guide wire was passed via the patent *foramen ovale* into the left atrium and a dilation was performed using an 8 mm balloon catheter (Z-Med II-X, 8 mm × 4 cm) (Figure 1). After the BAS, the PA mean pressure dropped to 48 mmHg and the CI improved from 1.38 L/min/m<sup>2</sup> to 1.97 L/min/m<sup>2</sup>. The arterial oxygen saturation decreased from 90% to 75%, and the partial oxygen pressure from 90 mmHg to 48 mmHg, with no difference in the partial pressure of carbon dioxide (CO<sub>2</sub>) (Table 1).

Inhaled prostanoids were started in combination with iv prostanoids and sildenafil; however, refractory hypoxaemia persisted and, unfortunately, three days after the BAS, the patient developed respiratory arrest and could not be resuscitated.

**Table 2.** Case 2. Echocardiographic parameters during the first hospitalisation on admission and pre-discharge, and during the second hospitalisation.

	Admission	Discharge	Second
PASP (mmHg)	100	75	95
RV-TDI (cm/s)	8	10	7
TAPSE (mm)	14	20	12
Pericardial fluid	no	no	yes

PASP – pulmonary arterial systolic pressure; RV-TDI – S – wave velocity for the right ventricle (tissue Doppler imaging); TAPSE – tricuspid annular plane systolic excursion.



**Figure 1.** 90° left oblique view during balloon atrial septostomy. PG – pigtail catheter; BAS – 8 mm atrial septostomy balloon; ICC – intracavitary ultrasound catheter.

## Discussion

The complication risks and death in pregnant women with cardiovascular disease are high. Pregnancy in women with PAH is associated with a high maternal mortality, estimated at between 30% and 56%,<sup>6</sup> as well as a high foetal risk.<sup>1</sup> According to a systematic review<sup>7</sup> of all published reports of pregnancies in women with PAH between 1997 and 2007, specific PAH treatment leads to improved outcome. Mortality in patients with idiopathic PAH decreased from 30 to 17%.

PAH detected after pregnancy seems to be a major complication with an unclear mechanism. Placental hypoxia induces the release of biologically active factors that affect the production/activity of various vascular mediators in the endothelium, smooth muscle and extracellular matrix, leading to severe vasoconstriction.<sup>8</sup> Vascular remodelling is also promoted and further vasoconstriction in the uterine and systemic circulation occur.

Our first case was a parturient with a favourable outcome after treatment with calcium channel blockers, while the second involved rapidly progressive postpartum pulmonary hypertension. As indicated,<sup>9</sup> she was treated with iv prostanoids and sildenafil, avoiding bosentan because of the abnormal liver function tests. Because our patient was in an unstable clinical condition, with repeated syncopal episodes, BAS was con-

sidered as a bridge to transplantation. This procedure increases preload, CO, and systemic oxygen transport, and is indicated in cases of failure of maximal medical therapy, persisting RV failure, and/or recurrent syncope, as a bridge to transplantation and when no other therapeutic options exist.<sup>9</sup> Stepwise balloon dilatation is the procedure of choice.<sup>10</sup> We believe that the refractory hypoxaemia developed in our patient was due to balloon overdilation during atrial septostomy. Data from an updated analysis<sup>11</sup> of the worldwide literature concerning atrial septostomy identify refractory hypoxaemia as the most common cause of death. In 223 cases, 82% with idiopathic PAH, the mortality rate was 1% at 24 h and 14.8% at 1 month. In patients who underwent successful BAS, significant clinical improvement and beneficial and long-lasting haemodynamic effects at rest were obtained.

Our two case reports allow us to suggest the possibility of a better prognosis in patients with PAH detected early in the clinical course. Our second patient sought the first medical contact while in functional status WHO class IV, with all indices identifying a worse prognosis profile and the need for lung transplantation as a last option. The vast majority of PAH patients with an indication for transplantation receive bilateral lungs, as reported by the International Society for Heart and Lung Transplantation Registry.<sup>12</sup> The overall 5-year survival following transplantation for PAH is estimated at 45-50%.<sup>12</sup>

Our knowledge of pregnancy-induced PAH is scanty, and it should be emphasised that the exact interactions between many pathobiological mechanisms in the initiation and progression of PAH are not well understood. The consequent increase in PVR causing RV overload, hypertrophy, failure and death, has sensitised the medical community to the early diagnosis of pulmonary hypertension and appropriate treatment, contributing to the best outcome for the patient.

## References

1. Braunwald's Heart Disease, 8th ed. Saunders; 2008. p. 1967-1968.
2. Kuklina EV, Callaghan WM. Cardiomyopathy and other myocardial disorders among hospitalizations for pregnancy in the United States: 2004-2006. *Obstet Gynecol.* 2010; 115: 93-100.
3. James KB, Healy BP. Heart disease arising during or secondary to pregnancy. *Cardiovasc Clin.* 1989; 19: 81-96.
4. Weiss BM, Hess OM. Pulmonary vascular disease and pregnancy: current controversies, management strategies, and perspectives. *Eur Heart J.* 2000; 21: 104-115.
5. Vogiatzis I, Hadjimiltiades S, Sachpekidis V, Parcharidis G. Spontaneous coronary artery dissection and acute myocardial infarction during pregnancy. *Hellenic J Cardiol.* 2010; 51: 74-80.
6. Weiss BM, Zemp L, Seifert B, Hess OM. Outcome of pulmonary vascular disease in pregnancy: a systematic overview from 1978 through 1996. *J Am Coll Cardiol.* 1998; 31: 1650-1657.
7. Bédard E, Dimopoulos K, Gatzoulis MA. Has there been any progress made on pregnancy outcomes among women with pulmonary arterial hypertension? *Eur Heart J.* 2009; 30: 256-265.
8. Sheppard SJ, Khalil RA. Risk factors and mediators of the vascular dysfunction associated with hypertension in pregnancy. *Cardiovasc Hematol Disord Drug Targets.* 2010; 10: 33-52.
9. Galiè N, Hoeper MM, Humbert M, et al. Guidelines for the diagnosis and treatment of pulmonary hypertension: the Task Force for the Diagnosis and Treatment of Pulmonary Hypertension of the European Society of Cardiology (ESC) and the European Respiratory Society (ERS), endorsed by the International Society of Heart and Lung Transplantation (ISHLT). *Eur Heart J.* 2009; 30: 2493-2537.
10. Sandoval J, Gaspar J, Pulido T, et al. Graded balloon dilation atrial septostomy in severe primary pulmonary hypertension. A therapeutic alternative for patients nonresponsive to vasodilator treatment. *J Am Coll Cardiol.* 1998; 32: 297-304.
11. Keogh AM, Mayer E, Benza RL, et al. Interventional and surgical modalities of treatment in pulmonary hypertension. *J Am Coll Cardiol.* 2009; 54: S67-77.
12. Trulock EP, Edwards LB, Taylor DO, Boucek MM, Keck BM, Hertz MI. Registry of the International Society for Heart and Lung Transplantation: twenty-third official adult lung and heart-lung transplantation report – 2006. *J Heart Lung Transplant.* 2006; 25: 880-892.